



Original Article

# Changes in Orbicularis Oris Superior and Masseter Muscle Activities After Upper Incisor Protrusion in Class II Division 2 Malocclusion: An Electromyographic Study

Irmak Ocak<sup>1</sup>, Abdullah Ruhi Soylu<sup>2</sup>, Müge Aksu<sup>3</sup>

<sup>1</sup>Department of Orthodontics, Ankara Medipol University, Faculty of Dentistry, Ankara, Turkey

<sup>2</sup>Department of Biophysics, Hacettepe University, School of Medicine, Ankara, Turkey

<sup>3</sup>Department of Orthodontics, Hacettepe University, Faculty of Dentistry, Ankara, Turkey

Cite this article as: Ocak I, Ruhi Soylu A, Aksu M. Changes in orbicularis oris superior and masseter muscle activities after upper incisor protrusion in Class II Division 2 malocclusion: An electromyographic study. *Turk J Orthod.* 2022;35(4):231-238.

## Main Points

- The incisor protrusion did not affect the electromyography activities of the orbicularis oris superior and masseter muscles at rest position.
- Differences in maximum contraction electromyography measurements of orbicularis oris superior and masseter muscles were observed after 6 months.
- Changes in functional structures should also be taken into account in terms of stability.

## ABSTRACT

**Objective:** This prospective study aimed to evaluate the orbicularis oris superior and masseter muscle activity changes after upper incisor protrusion in CII/2 malocclusion.

**Methods:** A total of 20 patients (mean age  $10.29 \pm 0.90$  years) with CII/2 malocclusion were selected for the study group. A total of 15 patients (mean age  $10.56 \pm 1.06$  years) with Angle Class I malocclusion were recruited as control. Upper incisors were protruded with utility arch in the study group. Muscle activities were evaluated with Biopac MP150 surface electromyography device before and after upper incisor proclination and at the 6-month retention. Orbicularis oris superior and left–right masseter muscles were recorded during rest electromyography and maximum contraction electromyography. Repeated measures and two-way repeated-measures analysis of variance with Bonferroni correction were used for statistical analysis.

**Results:** A significant change occurred over time in orbicularis oris superior ( $P < 0.001$ ), left masseter ( $P < 0.01$ ) and right masseter ( $P < 0.05$ ) maximum contraction electromyography in the CII/2 group. However, a significant difference was not found between groups  $P > 0.05$ . In the CII/2 group, orbicularis oris superior maximum contraction electromyography value was increased after upper incisor protrusion and this increase remained stable. Left masseter and right masseter maximum contraction electromyography measurements were decreased after protrusion and then increased after retention significantly. Rest electromyography values for all muscles were not statistically significant. No significant differences with the control group were found.

**Conclusion:** Upper incisor protrusion increased orbicularis oris superior activity and the increase remained stable after retention. Masseter activities decreased after protrusion and then increased to the initial values. These changes did not show significant differences with the control group.

**Keywords:** Angle Class II Division 2 malocclusion, EMG activity, orbicularis oris muscle, masseter muscle

## INTRODUCTION

Angle Class II Division 2 (CII/2) malocclusion is characterized by decreased overjet and increased overbite with severe retroclination of the upper incisors. Genetics is given importance in etiology, but environmental factors related to lips, cheeks, and tongue are also held responsible. While some studies hold the high lower lip line

**Corresponding author:** Müge Aksu, e-mail: muge.aksu@hacettepe.edu.tr

© Copyright 2021 by Turkish Orthodontic Society - Available online at turkjorthod.org

**Received:** December 30, 2021

**Accepted:** May 15, 2022

**Publication Date:**

December 30, 2022

responsible for the backward position of the upper incisors,<sup>1,2</sup> some studies point to strong masseter muscles and increased masticatory forces.<sup>3,4</sup>

Electromyography (EMG) involves monitoring and interpretation of electrical activities generated by muscle contraction. While evaluating the activities of the muscles, it is possible to record during rest and functions such as chewing, swallowing, and clenching. The aim of orthodontic treatment is not only to provide ideal occlusion but also to ensure balance and stability of the entire stomatognathic system. Therefore, electromyographic evaluations have become more important in diagnosing and monitoring orthodontic treatments, as it is a noninvasive, objective, and precise method.<sup>5</sup>

In recent studies, the orbicularis oris muscle activity of individuals with CII/2 malocclusion has been investigated and various results have been reported.<sup>2,6</sup> Lapatki et al.<sup>2</sup> found no statistically significant difference between the groups in which they evaluated the orbicularis oris inferior, orbicularis oris superior (OOS), depressor labii inferior, and mentalis muscle activities of patients with CII/2 and Angle Class I malocclusion. Lowe and Takada,<sup>6</sup> on the other hand, reported that the orbicularis oris muscle amplitudes at rest and during maximum intercuspation of CII/2 malocclusion were higher compared to Angle Class I and Angle Class II division 1 (CII/1) malocclusions. It was also stated that the amplitude was related to the retroclined upper central incisors and the occlusal plane.

It has been shown that the form and functions of the masticatory muscles are closely related to the morphological features of the muscles and related skeletal structures.<sup>7,8</sup> On the contrary, it is necessary to consider that the changes that will occur in the hard tissues during orthodontic treatment will also cause a response in the muscles. In this respect, the compatibility of functional structures of patients with CII/2 malocclusion to hard tissue changes occurring in the early development stage is unknown. Therefore, the first aim of this study was to investigate the muscle activities of Angle Class I and Angle CII/2 malocclusions. The secondary aim was to evaluate whether increasing the inclination of the upper incisors in CII/2 malocclusion causes any changes in the OOS and masseter muscle activities. The null hypothesis was that increasing the inclination of the upper incisors would not change the muscle activities.

## METHODS

A prospective study was conducted in accordance with the Declaration of Helsinki guidelines and was approved by the Ethics Committee of Hacettepe University (Approval number KA-15027). A total of 35 patients and their parents were informed about the purpose of this study, and they were asked to sign an informed consent form.

The study group consisted of 20 subjects (mean age:  $10.29 \pm 0.90$  years) with CII/2 malocclusion. The inclusion criteria in the study group were: (1) horizontal growth pattern, (2) overbite greater than 4 mm, (3) retroclined upper incisors, (4) cusp-to-cusp and/or Class 2 molar relationship, (5) no congenitally

missing upper incisors, and (6) no history of orthodontic treatment.

The control group, on the other hand, consisted of 15 Angle Class I malocclusion subjects (mean age:  $10.56 \pm 1.06$  years) with minimal crowding. Inclusion criteria for the control group were (1) normally inclined upper incisors, (2) no soft tissue incompetence, (3) no congenitally missing upper incisors, (4) orthognathic profile with normal facial growth pattern, and (5) no plan for any fixed or removable orthodontic appliance therapy.

Exclusion criteria for both groups were (1) having any systemic diseases or craniofacial deformities, (2) having any bad habits associated with perioral muscles, and (3) having any temporomandibular disorders.

## Initial Records

The aim of the study was to investigate whether changes in upper incisor position would have any effect on OOS, left masseter (LM), and right masseter (RM) muscles at rest and during 2 oral activities (tightening the lips and clenching teeth), and therefore, electromyographic evaluation was preferred.

Electromyographic activities were recorded before appliance insertion (T0), at the end of the incisor protrusion (T1), and at the end of 6-month retention (T2). During the study, no treatment was applied to the control group and dentition follow-up appointments were scheduled. Therefore, in coordination with the study group, control group recordings were taken at similar intervals between recordings.

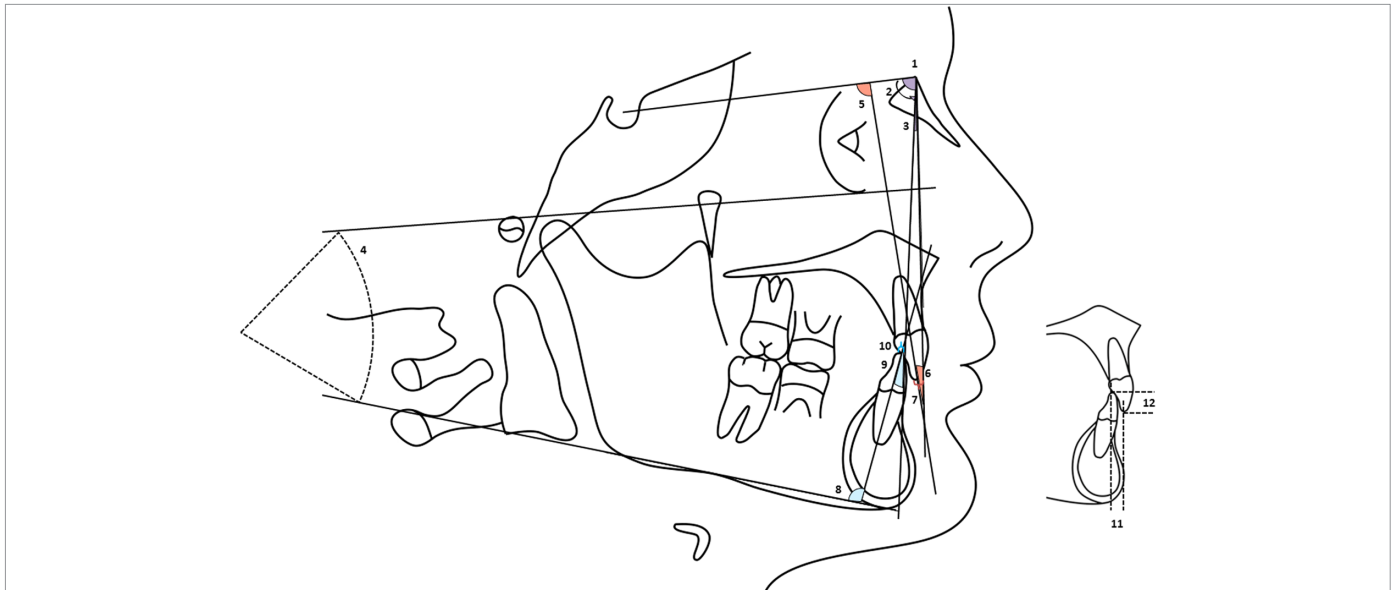
Digital lateral cephalometric radiographs of CII/2 patients were taken at T0, T1, and T2 stages, with the teeth in centric occlusion and the lips without tension in natural head position.

## Orthodontic Treatment Protocol

After T0 recordings were obtained from the study group, a passive transpalatal arch was applied to the maxillary first molars. The purpose of the transpalatal arch application was to increase the anchorage of the upper molar teeth. At the same appointment, conventional brackets (0.018-inch slots, Gemini, 3M Unitek, Monrovia, CA, USA) were bonded to the upper incisors. According to the amount of crowding, 0.016-inch or  $0.016 \times 0.016$ -inch nickel-titanium leveling utility arch was applied. After leveling was completed, the protrusion utility arch from  $0.016 \times 0.022$ -inch blue Elgiloy wire was applied. Subjects were observed every 4 weeks. The inclination of the upper incisors was evaluated only clinically to determine whether adequate protrusion was achieved and to avoid unnecessary radiation exposure. When overjet was approximately doubled and sufficient protrusion was obtained, all appliances were removed and records were taken at T1. Hawley retainer was applied as a 6-month retention period until T2.

## Radiographic Evaluation

Cephalometric measurements were analyzed using Dolphin Imaging software version 11.8 (Dolphin Imaging & Management Solutions, Chatsworth, Calif, USA). Lateral cephalometric analysis



**Figure 1.** Cephalometric measurements. (1) SNA angle, (2) SNB angle, (3) ANB angle, (4) FMA angle, (5) U1-SN angle, (6) U1-NA angle, (7) U1-NA distance, (8) IMPA, (9) L1-NB angle, (10) L1-NB distance, (11) overjet, and (12) overbite

were performed to define skeletal and dentoalveolar features in the study group. Cephalometric measurements are shown in Figure 1.

### Electromyographic Evaluation

Biopac MP150 device with EMG amplifier (Biopac Systems Inc., Calif, USA) was used to record muscle activities in T0, T1, and T2 stages. Ag/AgCl solid and self-adhesive bipolar electrodes (plusMED, Bio Protech Inc., Gangwon-do, Korea) were used to record surface electromyography (sEMG) activities. Electromyography amplifier gain, passband, common-mode rejection rate, and sampling frequency were 1000 $\times$ , 1-500 Hz, 80 dB, and 1000 Hz, respectively.

Subjects were asked to sit comfortably upright in a chair with their hands in their laps, without head support. Recordings were taken in an anechoic room to prevent individuals from being affected by external stimuli. However, the door of the anechoic room was not closed to avoid anxiety.

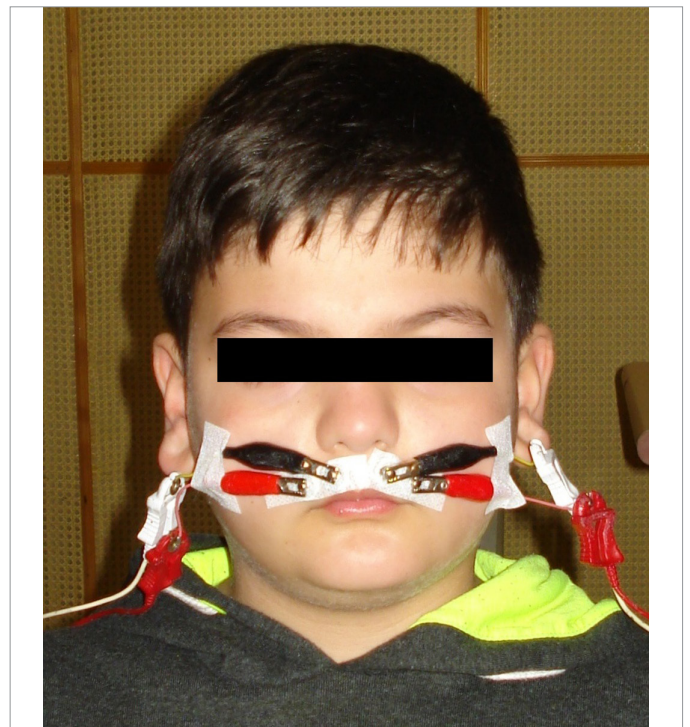Electromyographic recordings were taken from OOS, LM, and RM muscles. Before placing the electrodes, the skin was cleansed with alcohol and dried to reduce skin impedance.

Because the OOS muscle was small in size, the adhesive area around the electrodes was removed. The distance between the 2 electrodes was adjusted to be 1 cm, and they were attached 4 mm above the vermilion border with the help of plasters according to the technique described by Lapatki et al.<sup>9</sup> at an equal distance to both sides of the philtrum. The placement of the electrodes of the OOS muscle is shown in Figure 2. Masseter muscle electrodes were placed parallel to the muscle fibers, and the distance between the 2 electrodes was set to be 2 cm. The upper masseter electrode was aligned according to the technique described by Ferrario and Sforza,<sup>10</sup> coinciding with the

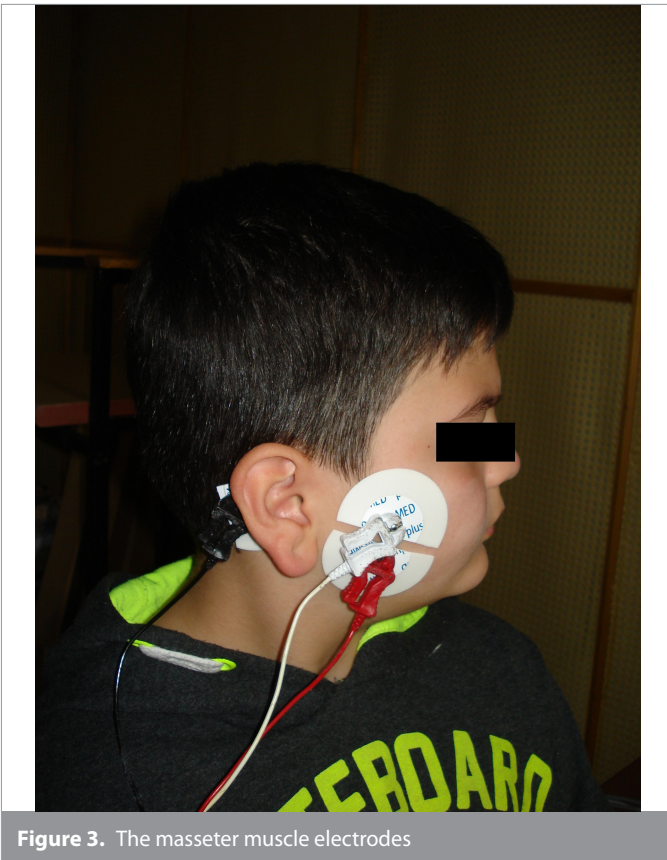intersection of the tragus-labial commissure and exocantion-gonion lines. A ground electrode was secured over the mastoid. The placement of the masseter muscle and ground electrodes is shown in Figure 3.

Electromyographic recordings were taken at the following positions:

1. *Physiological rest position:* Subjects were asked to look forward after sitting and waiting without moving their jaws



**Figure 2.** The orbicularis oris muscle electrodes



**Figure 3.** The masseter muscle electrodes

- and/or teeth. After stabilizing the position, recordings were taken for 6 seconds for each muscle group.
2. *Tightening of the lips:* For EMG recording of the OOS muscle, a tongue depressor was placed between the lips of the individuals in such a way that it would not contact their teeth, and the subjects were asked to tighten their lips as much as possible. The recording process continued for 10 s.
  3. *Clenching:* For EMG recording of masseter muscles, 2 cotton rolls were placed between the posterior teeth of the subjects on both sides, and they were asked to clench their teeth as much as possible. The recording process continued for 10 seconds.

Separate recordings were taken for each muscle group so that the electrodes did not interfere with the movement of the muscle. Lip tightening and teeth clenching recordings were repeated three times, and a 3-min rest period was given for the muscles between each recording. During the recordings, the sound with the command “increase” was repeated so that the recording would not be interrupted.

MATLAB (MathWorks, Mass, USA) was used to evaluate the EMG data. Signals were filtered with a 20-Hz high pass filter (6th order, Butterworth) to remove motion artifacts. A root-mean-square (RMS) filter (time window: 200 ms) was then applied to the signals. The lowest EMG amplitude within 2 seconds before the onset of maximum voluntary contraction (MVC) was defined by the software and recorded as a resting EMG (r-EMG). The highest RMS value within 6 seconds from the onset of MVC was automatically identified by the software and recorded as maximum

contraction (m-EMG). The reason why the recording after the first 6 seconds is not used in the evaluation is to prevent the disruptive effect of muscle fatigue. A single value was obtained by taking the arithmetic mean of the left and right OOS muscle measurements, and the LM and RM muscles were evaluated separately.

**Statistical Analysis**

Statistical Package of Social Sciences Statistics software (version 21; IBM Corp, Armonk, NY, USA) was used for data analysis. The normal distribution of data was confirmed by the Kolmogorov–Smirnov test. In repeated measurements, intra-observer reliability was evaluated with the intra-class correlation coefficient. All cephalometric measurements were performed by the first author (I.O.), and measurements of 5 patients were repeated within 15 days. Previously repeated measurements were used to assess the reliability of muscle activities. Descriptive statistics were expressed as mean ± standard deviation for continuous variables. Two groups were evaluated using the independent sample t-test for quantitative variables and the chi square test for categorical variables. Repeated-measures analysis of variance (ANOVA) was used to observe the differences of the variables in the groups according to the time periods. Two-way repeated-measures ANOVA was used to examine the main effects and interaction effects between malocclusion groups at all stages for EMG measurements. As post hoc multiple comparisons, Bonferroni correction was applied. A power calculation indicated that the achieved power for the study was 0.97. The results for  $P < .05$  were accepted to be significant statistically.

**RESULTS**

Data are normally distributed according to the Kolmogorov–Smirnov normality test. The intra-class correlation coefficient for cephalometric measurements is between 0.972 and 1.000, and for electromyographic measurements, it is in the range of 0.957–0.986. There was no statistically significant difference between the groups in terms of age and gender distribution ( $P > .05$ , Table 1).

Skeletal and dentoalveolar cephalometric measurements of the study group are presented in Table 2. Maxillomandibular discrepancy was slightly decreased ( $0.86^\circ$ ) according to the ANB angle ( $P < .001$ , Table 3). As shown in Table 3, measurements showing both the upper incisor position (U1-SN angle, U1-NA angle, U1-NA distance) and the lower incisor position (IMPA, L1-NB angle, L1-NB distance) are significant after protrusion increased significantly ( $P < .001$ , T1-T0) and did not change during retention

	Study Group	Control Group	P
Female	8	5	.960
Male	12	10	
Total	20	15	
Age (years) *	10.29 ± 0.90	10.56 ± 1.06	.418

\* Data expressed as mean ± standard deviation.

**Table 2.** Repeated measures ANOVA results for the skeletal and dentoalveolar lateral cephalometric measurements of study group

	T0	T1	T2	P
	Mean ± SD	Mean ± SD	Mean ± SD	
SNA (°)	80.73 ± 2.98	80.20 ± 3.27	80.30 ± 3.42	.099
SNB (°)	74.79 ± 3.02	74.82 ± 3.34	75.25 ± 3.45	.192
ANB (°)	5.92 ± 1.37	5.29 ± 1.64	5.06 ± 1.68	.000***
FMA (°)	20.80 ± 2.49	20.97 ± 2.72	21.19 ± 2.73	.117
U1-SN (°)	89.49 ± 5.69	108.91 ± 5.25	106.71 ± 6.00	.000***
U1-NA (°)	8.69 ± 5.37	28.70 ± 4.67	26.41 ± 3.99	.000***
U1-NA (mm)	-1.39 ± 1.62	4.90 ± 1.51	4.65 ± 1.24	.000***
IMPA (°)	95.50 ± 6.58	99.28 ± 5.36	97.75 ± 5.12	.000***
L1-NB (°)	19.27 ± 7.19	24.14 ± 5.69	22.88 ± 6.00	.000***
L1-NB (mm)	2.20 ± 2.31	3.25 ± 2.12	3.36 ± 2.29	.000***
Overjet (mm)	4.43 ± 1.11	8.75 ± 1.70	8.04 ± 1.73	.000***
Overbite (mm)	5.85 ± 1.15	5.08 ± 0.85	3.66 ± 1.40	.000***

SD, standard deviation. \*\*\*P < .001.

**Table 4.** Two-way ANOVA results for the electromyographic measurements

	P		
	Malocclusion	Treatment	Malocclusion-Treatment
OOS r-EMG (µV)	0.135	0.643	0.595
OOS m-EMG (µV)	0.213	0.000***	0.462
LM r-EMG (µV)	0.282	0.400	0.744
LM m-EMG (µV)	0.054	0.003**	0.279
RM r-EMG (µV)	0.735	0.499	0.506
RM m-EMG (µV)	0.093	0.010*	0.034*

EMG, electromyography; OOS, orbicularis oris superior; LM, left masseter muscle; RM, right masseter muscle; r-EMG, rest EMG; m-EMG, maximum contraction EMG.  
\*P < .05, \*\*P < .01, \*\*\*P < .001.

(P > .05, T2-T1). There was a statistically significant increase (P < .001, T1-T0) in the post-protrusion overjet (4.32 mm) and a slight but significant decrease after the retention period (P < .05, T2-T1, Table 3). Overbite decreased significantly by 0.78 mm after protrusion (P < .05, T1-T0) and continued to decrease significantly after the retention period (P < .001, T2-T1, Table 3).

A statistically significant change was observed in OOS m-EMG (P < .001), LM m-EMG (P < .01), and RM m-EMG (P < .05) measurements with treatment (Table 4). Interaction between malocclusion and treatment was observed only in RM m-EMG (P < .05, Table 4).

Comparison of electromyographic measurements between study and control groups is shown in Table 5. At the beginning of the treatment, a difference was observed between the study and control groups in RM m-EMG (P < .05, T0, Table 5). There was no difference between the groups after protrusion (P > .05, T1, Table 5), but there was a significant difference in LM m-EMG at the end of retention (P < .05, T2, Table 5).

Orbicularis oris superior maximum contraction electromyography increased significantly after protrusion (P < .001, T1-T0, Table 6) in the study group, and this increase remained constant (P < .05, T2-T0, Table 6). Left masseter and right masseter maximum contraction electromyography decreased significantly after protrusion (P < .01, T1-T0, Table 6) and increased significantly after retention (P < .05, T2-T1, Table 6). Changes in r-EMG measurements for all muscles were not statistically significant at all treatment stages (P > .05, Table 6).

**Table 3.** Lateral cephalometric changes of the study group in different treatment stages by Bonferroni Test

	T1-T0		T2-T1		T2-T0	
	Mean Difference ± SD	P	Mean Difference ± SD	P	Mean Difference ± SD	P
SNA (°)	-0.53 ± 0.26	0.169	0.10 ± 0.19	0.187	-0.43 ± 0.30	0.503
SNB (°)	0.03 ± 0.29	1.000	0.43 ± 0.20	0.145	0.46 ± 0.32	0.514
ANB (°)	-0.53 ± 0.21	0.055	-0.33 ± 0.20	0.333	-0.86 ± 0.20	0.001**
FMA (°)	0.17 ± 0.22	1.000	0.26 ± 0.94	0.080	0.40 ± 0.22	0.246
U1-SN (°)	19.43 ± 1.47	0.000***	-2.21 ± 0.97	0.107	17.22 ± 1.43	0.000***
U1-NA (°)	20.02 ± 1.45	0.000***	-2.30 ± 0.90	0.058	17.72 ± 1.31	0.000***
U1-NA (mm)	6.29 ± 0.43	0.000***	-0.26 ± 0.28	1.000	6.03 ± 0.30	0.000***
IMPA (°)	3.78 ± 0.76	0.000***	-1.53 ± 0.66	0.096	2.25 ± 0.74	0.020*
L1-NB (°)	4.88 ± 0.69	0.000***	-1.27 ± 0.63	0.172	3.61 ± 0.75	0.000***
L1-NB (mm)	1.06 ± 0.21	0.000***	0.11 ± 0.15	1.000	1.17 ± 0.20	0.000***
Overjet (mm)	4.32 ± 0.36	0.000***	-0.71 ± 0.23	0.019*	3.62 ± 0.36	0.000***
Overbite (mm)	-0.78 ± 0.24	0.014*	-1.42 ± 0.28	0.000***	-2.19 ± 0.25	0.000***

SD, standard deviation.  
\*P < .05, \*\*P < .01, \*\*\*P < .001.

**Table 5.** Comparison of electromyographic measurements according to the treatment stages between the study and control group by Bonferroni Test

	T0			T1			T2		
	Study Group	Control Group	P	Study Group	Control Group	P	Study Group	Control Group	P
OOS r-EMG (µV)	1.42 ± 0.31	1.62 ± 0.52	.162	1.43 ± 0.34	1.70 ± 0.59	.090	1.43 ± 0.40	1.56 ± 0.58	.437
OOS m-EMG (µV)	169.70 ± 53.63	162.36 ± 41.59	.663	205.45 ± 54.54	179.96 ± 33.02	.119	203.73 ± 49.88	184.36 ± 40.85	.229
LM r-EMG (µV)	1.27 ± 0.34	1.12 ± 0.43	.258	1.16 ± 0.34	1.12 ± 0.25	.688	1.14 ± 0.36	1.06 ± 0.27	.477
LM m-EMG (µV)	348.54 ± 208.39	259.09 ± 101.20	.136	247.58 ± 113.14	205.73 ± 74.71	.223	334.21 ± 166.97	221.81 ± 100.92	.028*
RM r-EMG (µV)	1.21 ± 0.49	1.15 ± 0.37	.663	1.06 ± 0.27	1.17 ± 0.27	.217	1.07 ± 0.37	1.11 ± 0.31	.769
RM m-EMG (µV)	356.25 ± 225.13	225.39 ± 106.08	.045*	227.41 ± 107.55	219.33 ± 104.33	.825	318.07 ± 135.59	243.07 ± 119.45	.098

EMG, electromyography; OOS, orbicularis oris superior; LM, left masseter muscle; RM, right masseter muscle; r-EMG, rest EMG; m-EMG, maximum contraction EMG. Data expressed as mean ± standard deviation. \*P < .05.

**Table 6.** EMG changes in different treatment stages between study and control group by Bonferroni Test

	Group	T1-T0		T2-T1		T2-T0	
		Mean Difference ± SD	P	Mean Difference ± SD	P	Mean Difference ± SD	P
OOS r-EMG (µV)	Study group	0.01 ± 0.10	1.000	0.01 ± 0.09	1.000	0.02 ± 0.10	1.000
	Control group	0.09 ± 0.11	1.000	-0.14 ± 0.10	0.556	-0.05 ± 0.10	1.000
OOS m-EMG (µV)	Study group	35.75 ± 8.29	.000***	-1.73 ± 10.97	1.000	34.03 ± 9.57	.003**
	Control group	17.60 ± 9.57	.225	4.40 ± 12.66	1.000	22.00 ± 11.05	.164
LM r-EMG (µV)	Study group	-0.11 ± 0.10	.838	-0.02 ± 0.08	1.000	-0.13 ± 0.10	.546
	Control group	0.00 ± 0.11	1.000	-0.06 ± 0.10	1.000	-0.06 ± 0.11	1.000
LM m-EMG (µV)	Study group	-100.96 ± 29.72	.005**	86.63 ± 23.24	.002**	-14.33 ± 33.72	1.000
	Control group	-53.37 ± 34.32	.388	16.09 ± 26.84	1.000	-37.28 ± 38.94	1.000
RM r-EMG (µV)	Study group	-0.16 ± 0.12	.618	0.02 ± 0.08	1.000	-0.14 ± 0.10	.546
	Control group	0.03 ± 0.14	1.000	-0.07 ± 0.09	1.000	-0.04 ± 0.12	1.000
RM m-EMG (µV)	Study group	-128.84 ± 32.20	.001**	90.66 ± 21.64	.001**	-38.18 ± 34.85	.844
	Control group	-6.06 ± 37.18	1.000	23.74 ± 24.99	1.000	17.68 ± 40.24	1.000

EMG, electromyography; SD, standard deviation; OOS, orbicularis oris superior; LM, left masseter muscle; RM, right masseter muscle; r-EMG, rest EMG; m-EMG, maximum contraction EMG. \*\*P < .01, \*\*\*P < .001.

**DISCUSSION**

The goal of orthodontic treatment is not only to align the teeth but also to provide a balanced chewing pattern with balanced muscle activities. Therefore, determining the etiology and post-treatment changes originating from soft tissues is very important for the success of orthodontic treatment.

CII/2 malocclusion is characterized by dental features such as retroclined upper incisors and deep bite. However, in addition to dental features, skeletal pattern, facial profile, and muscular properties are also very characteristic. It has been stated that genetics is not the only factor affecting CII/2 malocclusion,<sup>11</sup> that the high lip line is associated with retroclination of the upper incisors.<sup>1,2,12</sup> Lapatki et al.<sup>13</sup> confirmed that the risk of relapse is high unless etiologic factors are eliminated during treatment. Therefore, possible etiological factors associated with the perioral muscles should be identified and monitored for the stability of orthodontic treatment. This study was conducted to evaluate the changes in the OOS and masseter muscles with upper incisor protrusion in CII/2 malocclusion.

In the present study, spontaneous protrusion of the lower incisors occurred with the protrusion of the upper incisors. Overjet increased significantly while overbite decreased. Timmons<sup>14</sup> reported that protrusion of the upper incisors and reduction of the overbite with orthodontic treatment resulted in the spontaneous forward repositioning of the mandible. Unlocking the mandible following proclination of the upper incisors in growing patients allowed the mandible to grow horizontally.<sup>15</sup> Similarly in our study, insignificant changes were observed in SNA and SNB angles, and ANB angle was significantly decreased by about 1°. This significance was associated with spontaneous growth of the mandible.

In addition to technical factors, age, gender, skeletal morphology, bad oral habits, skin/soft tissue thickness, and psychological factors affect EMG results. Experimental stress causes an increase in masticatory muscle EMG activities.<sup>16</sup> Therefore, it is important for the patient to be in a quiet place away from distractions to avoid anxiety and stress. Additionally, as a different method, Ingervall and Thüer<sup>17</sup> suggested excluding the first records from the study to minimize the effects of anxiety. In our study, patients

were seated in an anechoic room so that they could not see the computer screen, and all electronic devices were turned off to minimize external factors.

The literature on the relationship between malocclusion types and electromyographic activities of facial and masticatory muscles is inconclusive. Antonini et al.<sup>18</sup> reported that there were significant differences between CII/2 and Angle Class III malocclusions in the activities of the masticatory muscles during chewing and swallowing but not at rest. In a study by Lowe and Takada,<sup>6</sup> orbicularis oris muscle activities increased in CII/2 malocclusion during the rest and maximum intercuspation when compared with Angle Class I and CII/1 malocclusion. In another study, no significant difference was found between Angle Class I and CII/2 malocclusion in terms of orbicularis oris muscle activities.<sup>2</sup> According to our results, it was determined that malocclusions did not affect the activities of both OOS and masseter muscles. Contrary to our findings, Petrovic et al.<sup>19</sup> showed that masseter muscle activity was lower in CII/2 malocclusion compared to Angle Class I occlusion for both rest and MCV measurements.

Electromyography is also used to evaluate the efficacy of treatment and orthodontic appliances. However, there are few studies examining muscle activity changes with orthodontic treatment in CII/2 malocclusion. In a study examining the bio-electrical activity of masticatory muscles during activator therapy in CII/2 malocclusion, it was reported that muscle activities increased in the first year of treatment and decreased after a year of treatment.<sup>19</sup> Thüer et al.<sup>20</sup> reported that no significant change in masticatory muscle activities was seen at the end of activator therapy, while there were significant changes during treatment periods. Unlike our study, there was an increase in OOS and a decrease in the masseter muscle, which is a significant change in the maximum contraction of all muscles after treatment.

It is known that the postural activity of the orbicularis oris muscle is an important factor in incisor position. Few studies have shown that orbicularis oris muscle activity affects the inclination of the upper incisors.<sup>5,21-23</sup> However, Lowe<sup>24</sup> stated that the activity of the superior orbicularis oris muscle did not appear to be associated with the inclination of the upper incisors, and Ahlgren et al.<sup>25</sup> found a negative correlation between them. From a different perspective, we evaluated the effect of the upper incisor position on muscle activities and determined that the protrusion of the upper incisors and the responses of the OOS and masseter muscles were different. While OOS r-EMG measurements were not significant, the OOS m-EMG value increased due to the protrusion of the upper incisors, and this increase remained stable at the end of the 6-month retention period. Also, while the resting measurements were not significant, the LM m-EMG and RM m-EMG measurements decreased statistically significantly after protrusion and increased significantly after the retention period.

The first step in the treatment of CII/2 malocclusion is to correct the position of the upper incisors and convert the patient to a CII/1 malocclusion. The same protocol was followed in this study,

and the position of the lips changed after protrusion as expected. Due to the new position of both teeth and lips, the performance of oral functions also changes. Soft tissues exert more effort to perform the same functions. Tosello et al.<sup>26</sup> reported that OOS muscle activity was higher during tightening of their lips in individuals with CII/1 malocclusion and incompetent lips. As in our study, increased OOS muscle activity is thought to compensate for other perioral muscle movements to maintain proper function. This raises another point regarding the retention of CII/2 malocclusion, as this malocclusion has always been thought to be prone to relapse.<sup>27</sup> Our results indicate that increased OOS muscle activity on upper incisors that do not return to the initial value supports the idea of the possibility of relapse.

Removable acrylic plate treatment was applied by Thüer et al.<sup>20</sup> to evaluate changes in masticatory muscle activities. The authors found that the activity of the anterior and posterior temporal muscles was decreased during protrusion and intrusion of the upper incisors, whereas the activity of the masseter muscles was not significant. In the current study, LM and RM muscles were evaluated and discussed together. The reason for this is the masseter muscles can be clinically affected by many individual factors such as chewing patterns, eating habits, and pain caused by tooth eruption and therefore, subjects generally showed a predominance to the one side. In accordance with our study, Ferrario et al.<sup>28</sup> showed a predominance on the right side. The masseter muscle activities decreased statistically significantly after protrusion, while they increased significantly after the retention period. We assume that these results in our study are related not only to upper incisor protrusion but also to fixed treatment mechanics and changes in occlusion. Two studies evaluating anterior temporalis and masseter muscle activities with flexible fixed functional appliances reported that muscle activities decreased significantly after the first month of functional appliance therapy and returned to pre-appliance levels toward the end of 6 months after treatment.<sup>29,30</sup> Miyamoto et al.<sup>31</sup> stated that the masseter muscle activity decreased after fixed orthodontic treatment and this decrease returned to normal after 6 months. In accordance with the literature, our findings were thought to result from pain and discomfort during orthodontic treatment and neuromuscular adaptations after appliance removal.

This is the first study to investigate muscle changes after upper incisor protrusion via fixed appliances. Limitations of this study may be the small number of patients in the groups and the fact that tooth transitions may affect the clenching pattern, muscle activity, and discomfort. However, understanding the effects of early treatment in CII/2 malocclusion is important both to prevent the severity of the malocclusion and to obtain long-term stable treatment results. In further studies, our study design can be used to examine muscle changes that occur at different malocclusions. Our results show that OOS and masseter muscle activities are affected by the protrusion of the upper incisors. There will be a risk of relapse without a clear understanding of the etiological factors of CII/2 malocclusion. As a result, orthodontists should consider changes in jaw muscle activities during orthodontic treatment.

## CONCLUSION

- Malocclusions did not affect the activities of both OOS and masseter muscles.
- The activity of OOS muscle increased after maxillary incisor protrusion, and this increase remained stable after the retention period.
- The activities of LM and RM activities decreased after protrusion and increased back to initial values after the retention period.
- Further long-term follow-up studies are required to evaluate muscle activity changes due to growth and orthodontic treatment.

**Ethics Committee Approval:** Ethical committee approval was received from the Ethics Committee of Hacettepe University (Approval No: KA-15027).

**Informed Consent:** Written informed consent was obtained from all participants who participated in this study.

**Peer-review:** Externally peer-reviewed.

**Author Contributions:** Concept – I.O., M.A.; Design – I.O., M.A.; Supervision – A.R.S., M.A.; Materials – I.O.; Data Collection and/or Processing – I.O., A.R.S.; Analysis and/or Interpretation – I.O., A.R.S., M.A.; Literature Review – I.O., M.A.; Writing – I.O., M.A.; Critical Review – A.R.S., M.A.

**Acknowledgments:** The authors would like to thank Jale Karakaya for her assistance with the statistical analysis.

**Declaration of Interests:** The authors have no conflicts of interest to declare.

**Funding:** This study was supported by Hacettepe University Scientific Research Coordination Unit (Project Number: TDH-2017-10747).

## REFERENCES

- Lapatki BG, Klatt A, Schulte-Mönting J, Jonas IE. Dentofacial parameters explaining variability in retroclination of the maxillary central incisors. *J Orofac Orthop.* 2007;68(2):109-123. [CrossRef]
- Lapatki BG, Mager AS, Schulte-Mönting J, Jonas IE. The importance of the level of the lip line and resting lip pressure in Class II Division 2 malocclusion. *J Dent Res.* 2002;81(5):323-328. [CrossRef]
- Bishara SE. Class II Malocclusions: diagnostic and clinical considerations with and without treatment. *Semin Orthod.* 2006;12(1):11-24. [CrossRef]
- Katsavrias EG. Morphology of the temporomandibular joint in subjects with Class II Division 2 malocclusions. *Am J Orthod Dentofacial Orthop.* 2006;129(4):470-478. [CrossRef]
- Woźniak K, Piątkowska D, Lipski M, Mehr K. Surface electromyography in orthodontics—a literature review. *Med Sci Monit.* 2013;19:416-423. [CrossRef]
- Lowe AA, Takada K. Associations between anterior temporal, masseter, and orbicularis oris muscle activity and craniofacial morphology in children. *Am J Orthod.* 1984;86(4):319-330. [CrossRef]
- Van Spronsen PH, Koolstra JH, Van Ginkel FC, Weijs WA, Valk J, Prahl-Andersen B. Relationships between the orientation and moment arms of the human jaw muscles and normal craniofacial morphology. *Eur J Orthod.* 1997;19(3):313-328. [CrossRef]
- Benington PCM, Gardener JE, Hunt NP. Masseter muscle volume measured using ultrasonography and its relationship with facial morphology. *Eur J Orthod.* 1999;21(6):659-670. [CrossRef]
- Lapatki BG, Stegeman DF, Jonas IE. A surface EMG electrode for the simultaneous observation of multiple facial muscles. *J Neurosci Methods.* 2003;123(2):117-128. [CrossRef]
- Ferrario VF, Sforza C. Coordinated electromyographic activity of the human masseter and temporalis anterior muscles during mastication. *Eur J Oral Sci.* 1996;104(5-6):511-517. [CrossRef]
- Ruf S, Pancherz H. Class II Division 2 malocclusion: genetics or environment? A case report of monozygotic twins. *Angle Orthod.* 1999;69(4):321-324. [CrossRef]
- Karlsen AT. Craniofacial characteristics in children with Angle Class II div. 2 Malocclusion combined with extreme deep bite. *Angle Orthod.* 1994;64(2):123-130. [CrossRef]
- Lapatki BG, Klatt A, Schulte-Mönting J, Stein S, Jonas IE. A retrospective cephalometric study for the quantitative assessment of relapse factors in cover-bite treatment. *J Orofac Orthop.* 2004;65(6):475-488. [CrossRef]
- Timmons LS. Induced change in the anteriorposterior relationship of the jaws. *Angle Orthod.* 1972;42(3):245-251. [CrossRef]
- Erickson LP, Hunter WS, Class II. Class II, Division 2 treatment and mandibular growth. *Angle Orthod.* 1985;55(3):215-224. [CrossRef]
- Tsai CM, Chou SL, Gale EN, McCall WD. Human masticatory muscle activity and jaw position under experimental stress. *J Oral Rehabil.* 2002;29(1):44-51. [CrossRef]
- Ingervall B, Thüer U. Temporal muscle activity during the first year of Class II, division 1 malocclusion treatment with an activator. *Am J Orthod Dentofacial Orthop.* 1991;99(4):361-368. [CrossRef]
- Antonini G, Colantonio L, Macretti N, Lenzi GL. Electromyographic findings in Class II division 2 and Class III malocclusions. *Electromyogr Clin Neurophysiol.* 1990;30(1):27-30.
- Petrović D, Vujkov S, Petronijević B, Šarčević I, Stojanac I. Examination of the bioelectrical activity of the masticatory muscles during Angle's Class II division 2 therapy with an activator. *Vojnosanit Pregl.* 2014;71(12):1116-1122. [CrossRef]
- Thüer U, Ingervall B, Bürgin W, Demisch A. No posterior mandibular displacement in Angle Class II, division 2 malocclusion as revealed with electromyography and signographography. *Eur J Orthod.* 1992;14(2):162-171. [CrossRef]
- Jung MH, Yang WS, Nahm DS. Effects of upper lip closing force on craniofacial structures. *Am J Orthod Dentofacial Orthop.* 2003;123(1):58-63. [CrossRef]
- Jung MH, Yang WS, Nahm DS. Maximum closing force of mentolabial muscles and type of malocclusion. *Angle Orthod.* 2010;80(1):72-79. [CrossRef]
- Siqueira VCvd, Sousa MAd, Bérzin F, Casarini CAS. Electromyographic analysis of the orbicularis oris muscle in youngsters with Class II, Division 1 and normal occlusion. *Dent Press J Orthod.* 2011;16(5):54-61. [CrossRef]
- Lowe AA. Correlations between orofacial muscle activity and craniofacial morphology in a sample of control and anterior open-bite subjects. *Am J Orthod.* 1980;78(1):89-98. [CrossRef]
- Ahlgren JGA, Ingervall BF, Thilander BL. Muscle activity in normal and postnormal occlusion. *Am J Orthod.* 1973;64(5):445-456. [CrossRef]
- Tosello DO, Vitti M, Berzin F. EMG activity of the orbicularis oris and mentalis muscles in children with malocclusion, incompetent lips and atypical swallowing-Part II. *J Oral Rehabil.* 1999;26(8):644-649. [CrossRef]
- Selwyn-Barnett BJ. Rationale of treatment for Class II division 2 malocclusion. *Br J Orthod.* 1991;18(3):173-181. [CrossRef]
- Ferrario VF, Sforza C, Miani Jr A, D'Addona A, Barbini E. Electromyographic activity of human masticatory muscles in normal young people. Statistical evaluation of reference values for clinical applications. *J Oral Rehabil.* 1993;20(3):271-280. [CrossRef]
- Sood S, Kharbanda OP, Duggal R, Sood M, Gulati S. Muscle response during treatment of Class II Division 1 malocclusion with Forsus Fatigue Resistant Device. *J Clin Pediatr Dent.* 2011;35(3):331-338. [CrossRef]
- Sood S, Kharbanda OP, Duggal R, Sood M, Gulati S. Neuromuscular adaptations with flexible fixed functional appliance—a 2-year follow-up study. *J Orofac Orthop.* 2011;72(6):434-445. [CrossRef]
- Miyamoto K, Ishizuka Y, Tanne K. Changes in masseter muscle activity during orthodontic treatment evaluated by a 24-hour EMG system. *Angle Orthod.* 1996;66(3):223-228. [CrossRef]